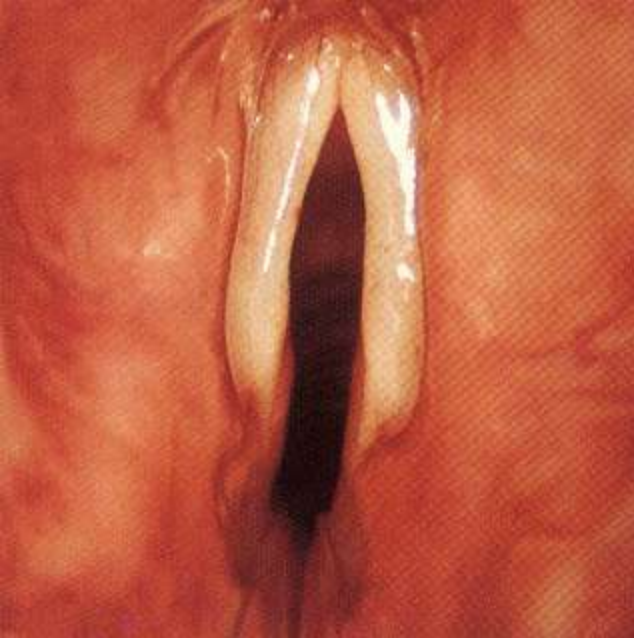
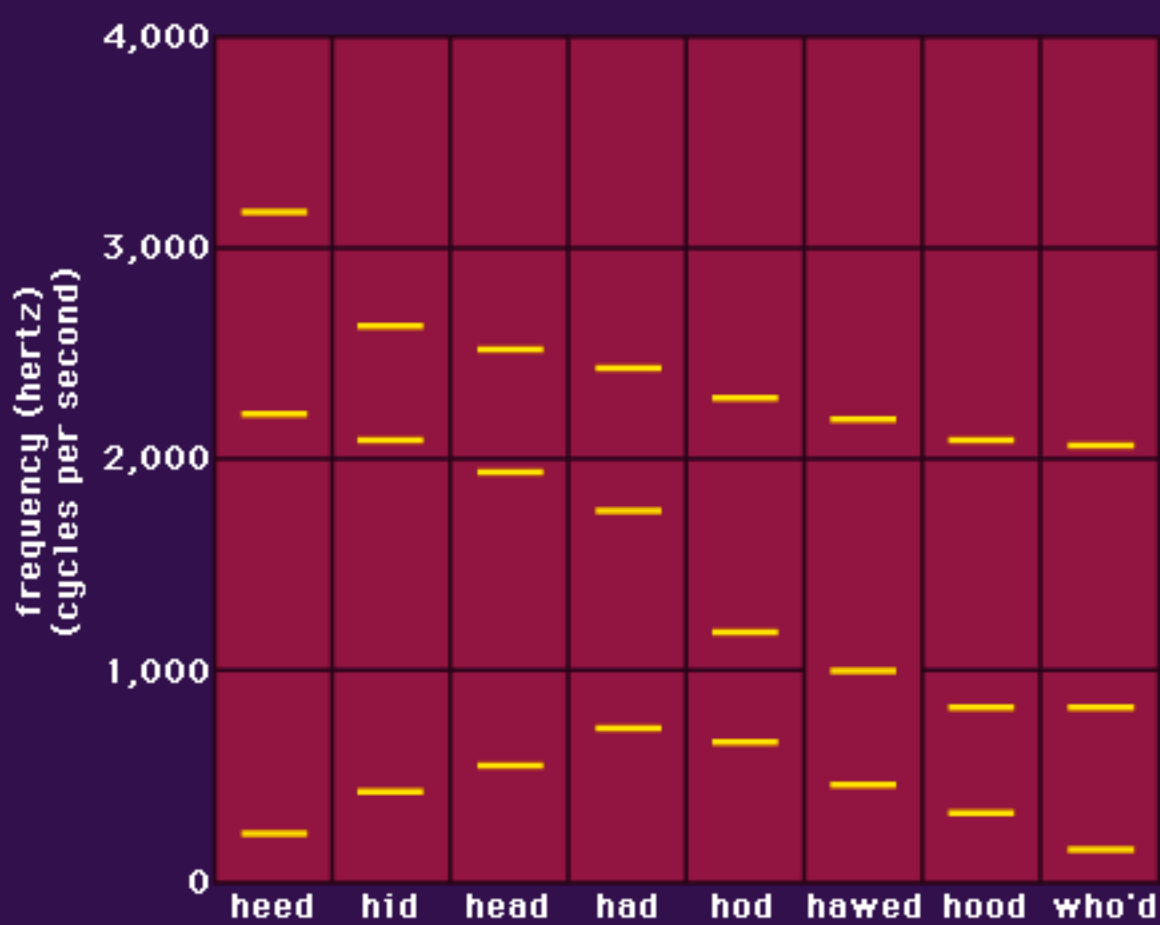


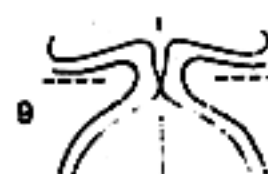
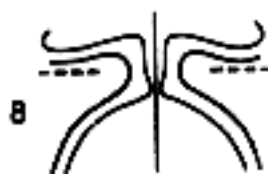
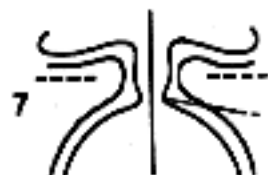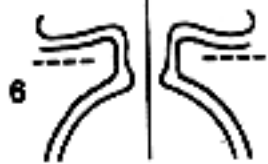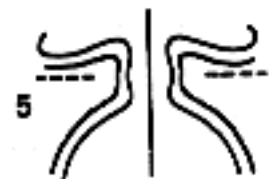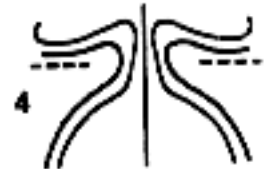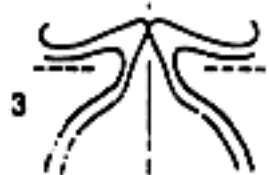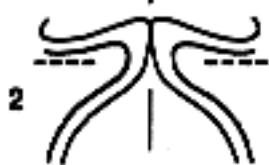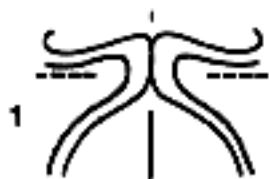ACK!

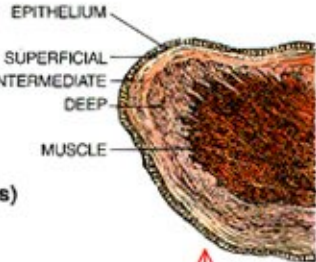
Physics, ACK!







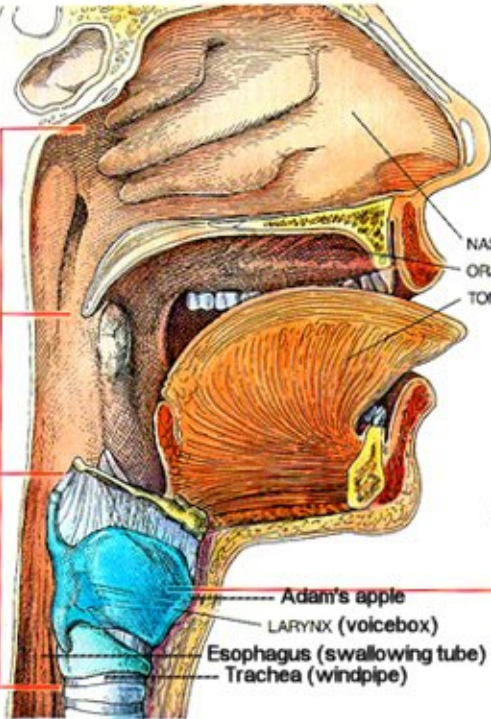
CROSS SECTION OF VOCAL FOLD



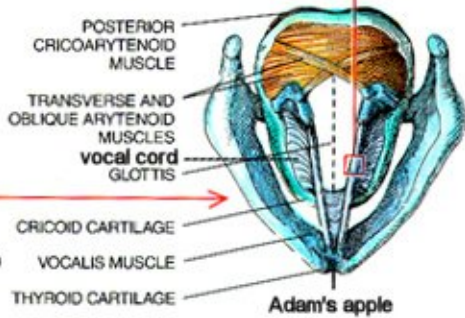
NASOPHARYNX

OROPHARYNX

LARYNGOPHARYNX



CROSS SECTION OF LARYNX (FROM ABOVE)



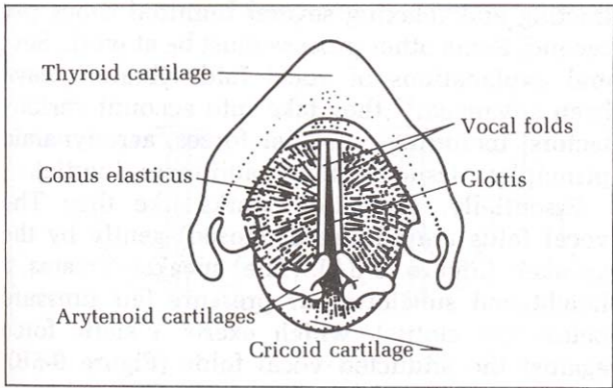
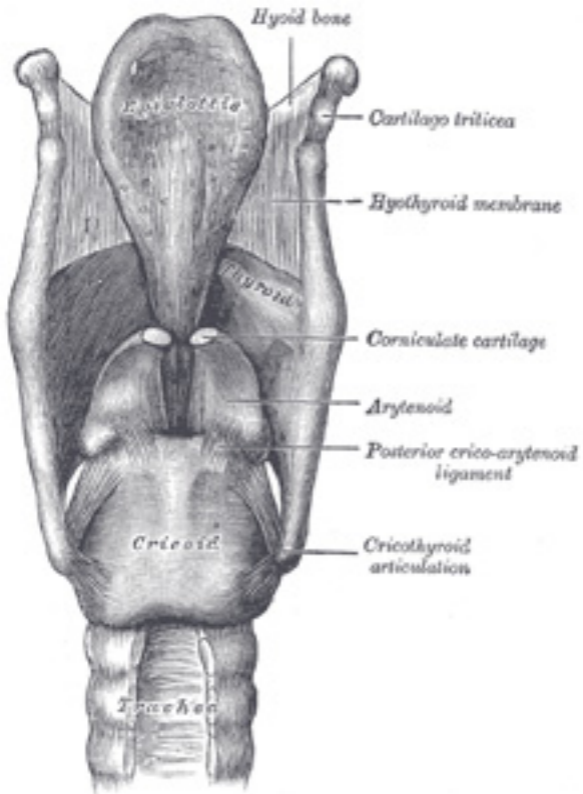


Figure 9-3. The conus elasticus and the vocal folds as seen from above.



Sulcus terminalis

Foramen cecum

Tongue

Vallcula

Median glosso-epiglottic fold

Lateral glosso-epiglottic fold

Epiglottis

Tubercle

Greater cornu of hyoid bone

Aryepiglottic fold

Sup. cornu of thyroid cart.

Glottis

Ventricular fold

Cuneiform cartilage

Ventricle

Half of hyarynx

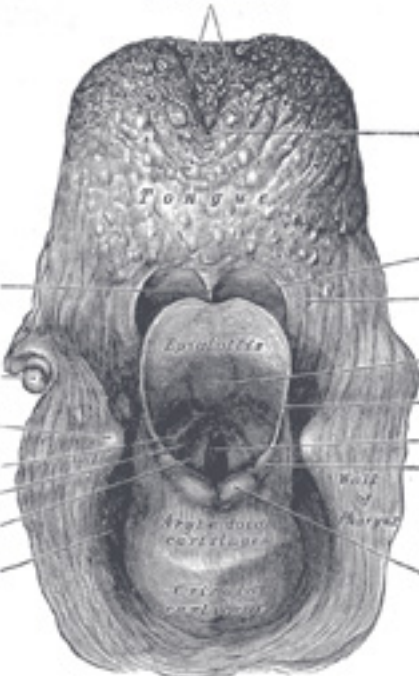
Vocal fold

Arytenoid cartilage

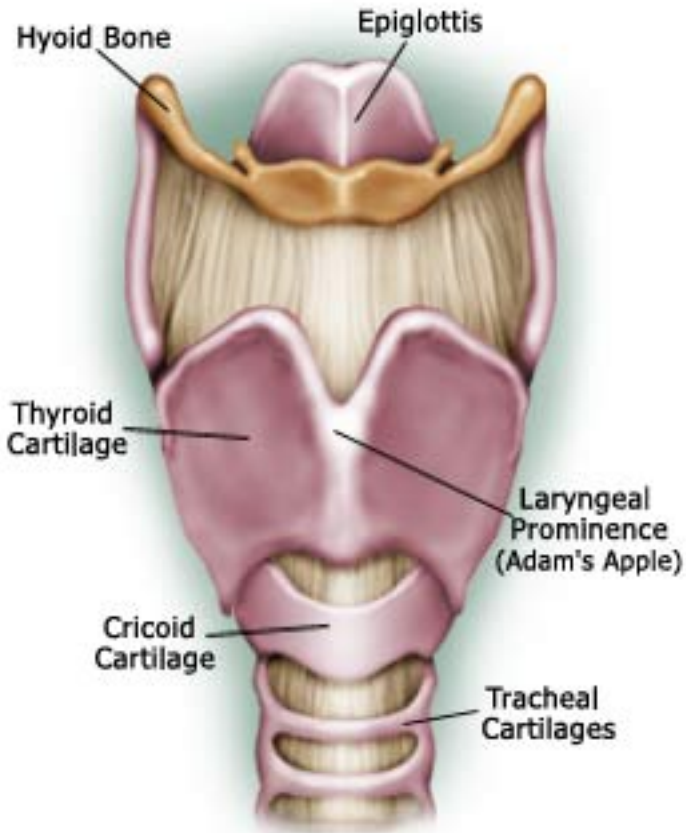
Corniculate cartilage

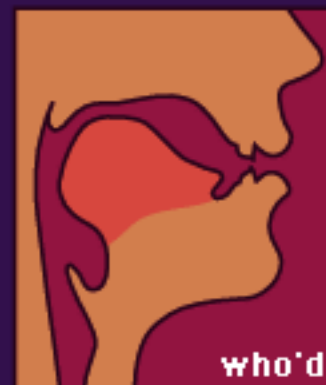
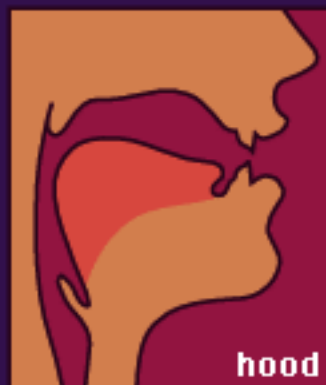
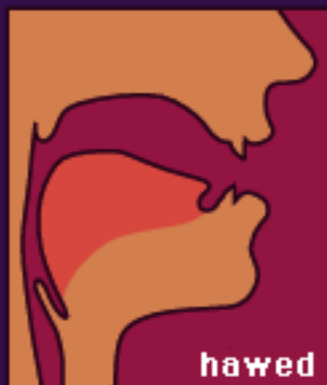
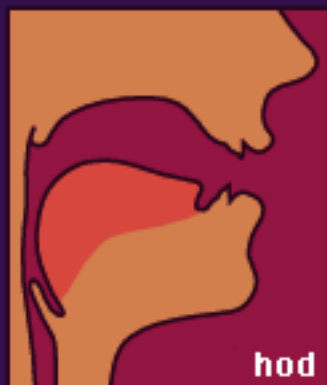
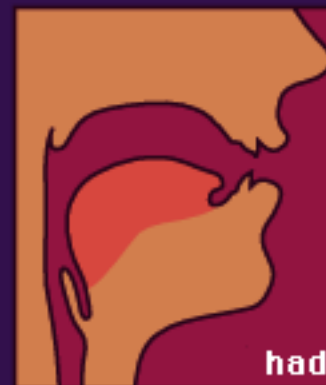
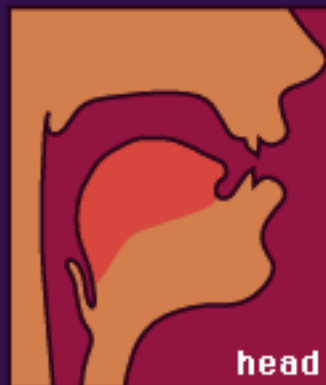
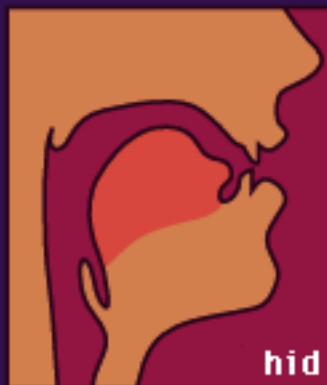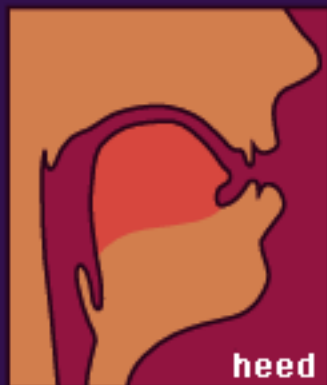Pyriform sinus

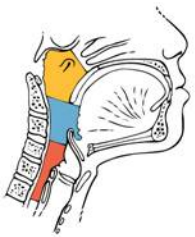
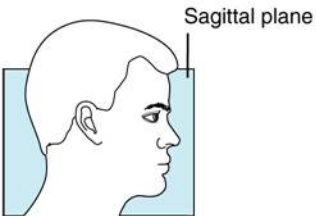
Cricoid cartilage



Larynx

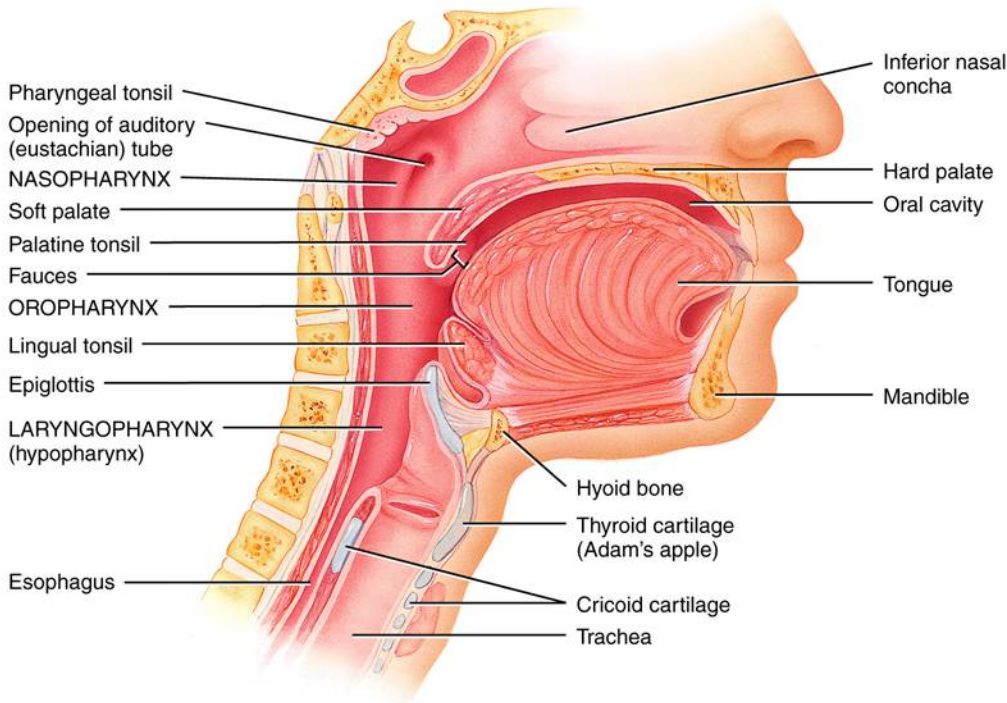




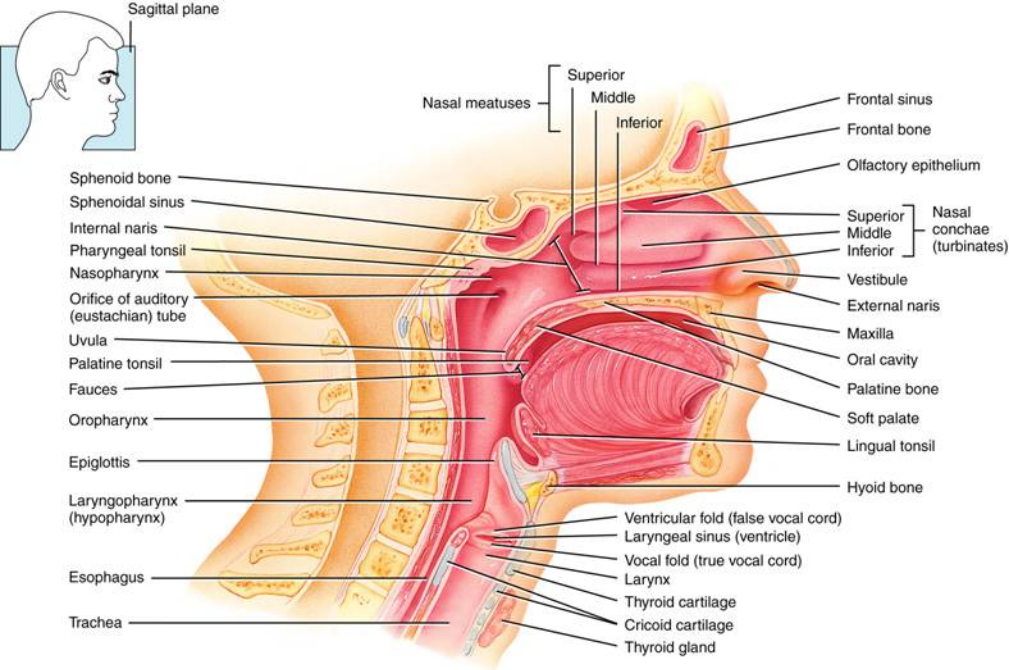


- Nasopharynx
- Oropharynx
- Laryngopharynx

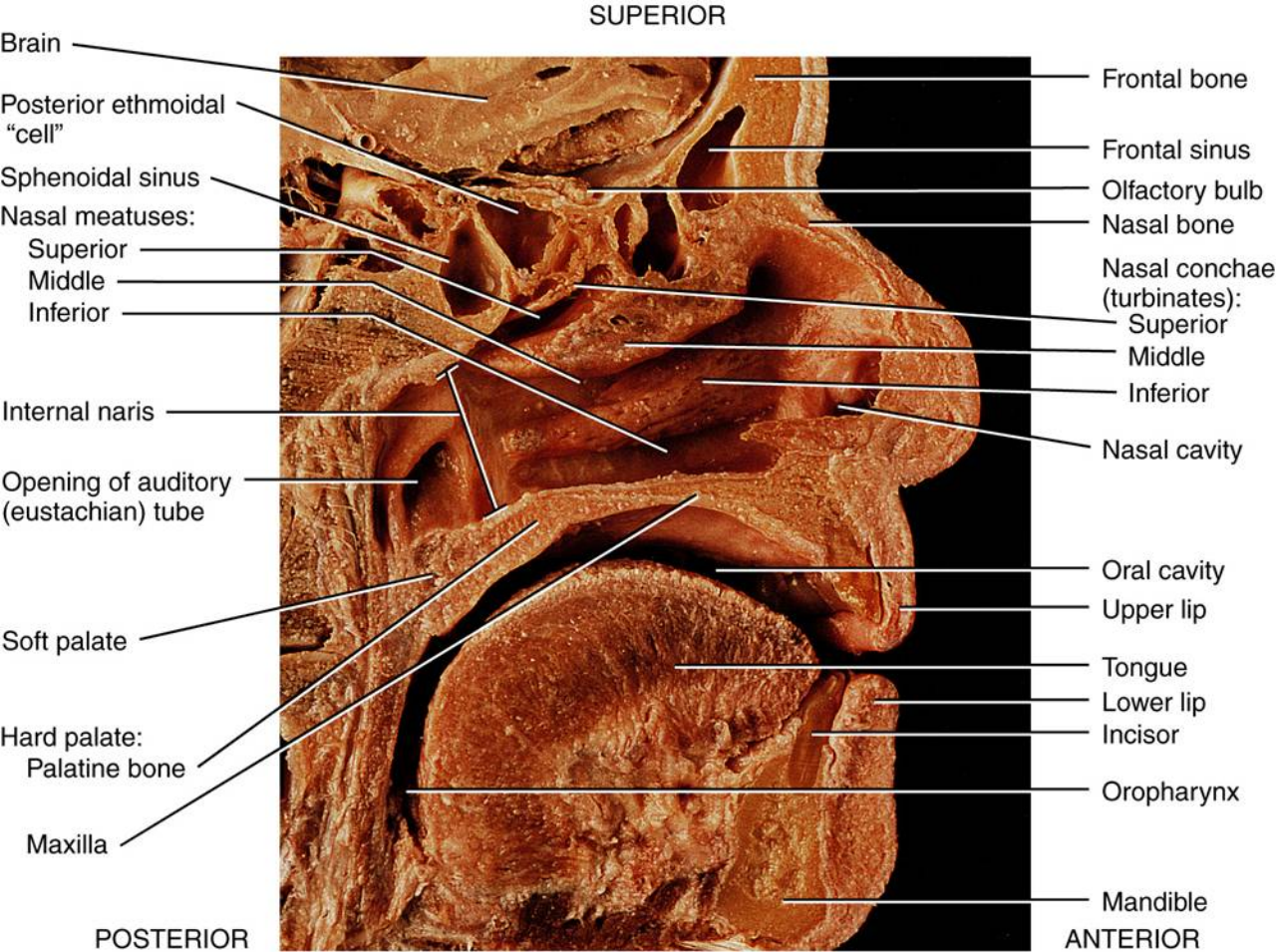
Regions of the pharynx



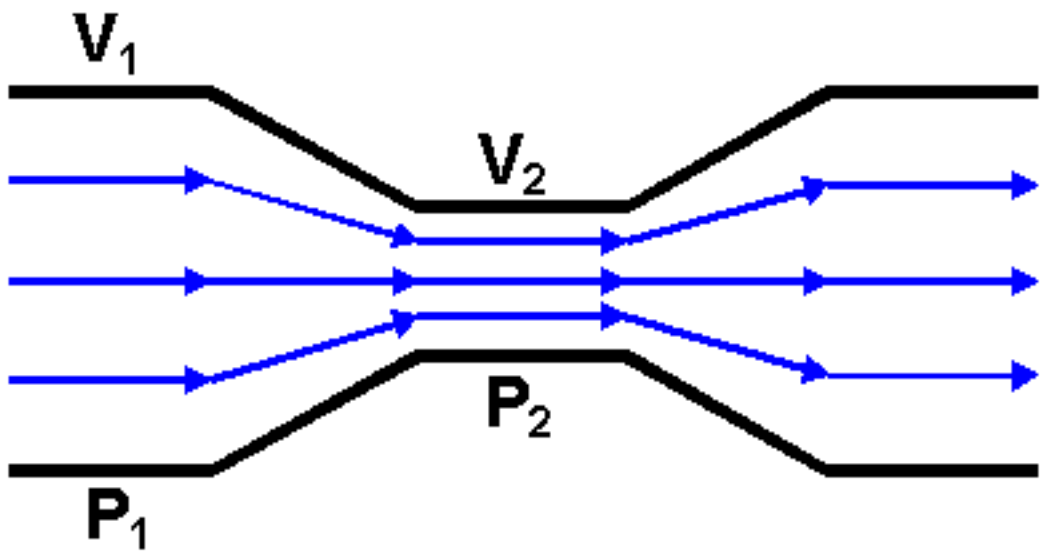
Sagittal section showing the regions of the pharynx

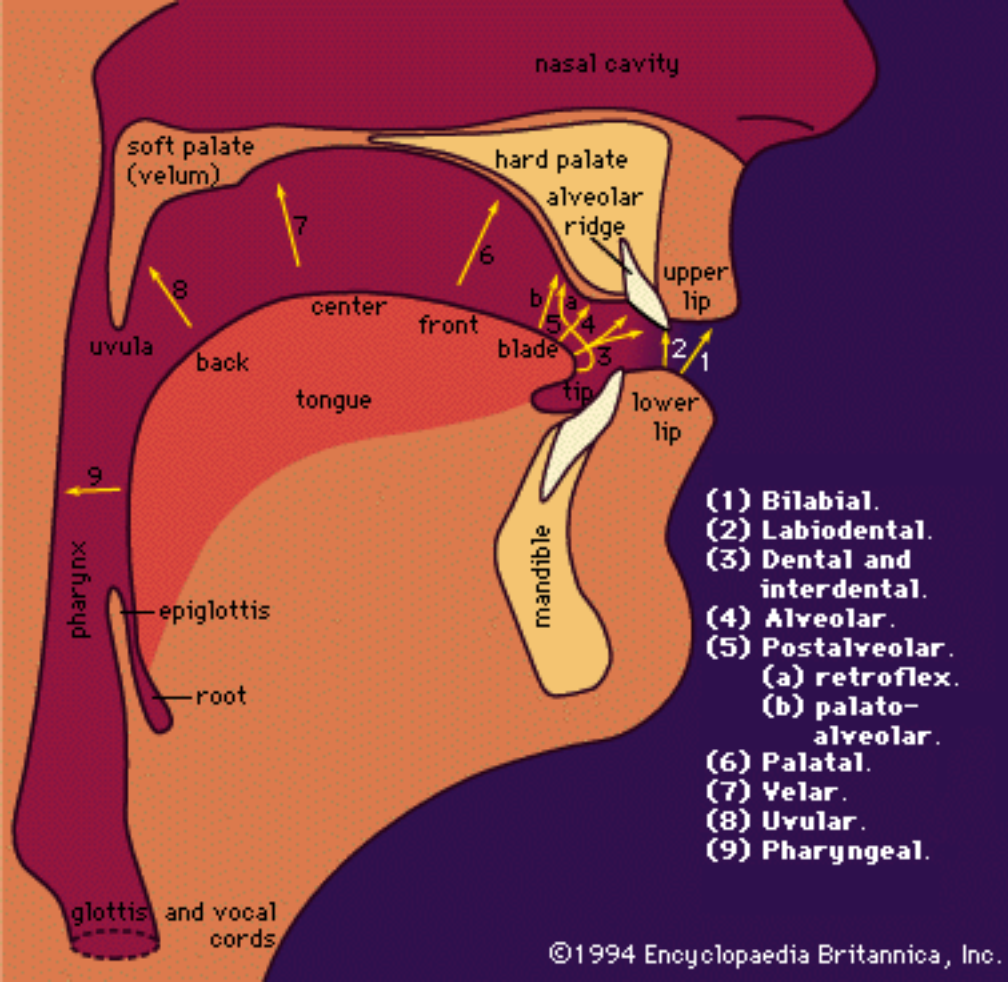


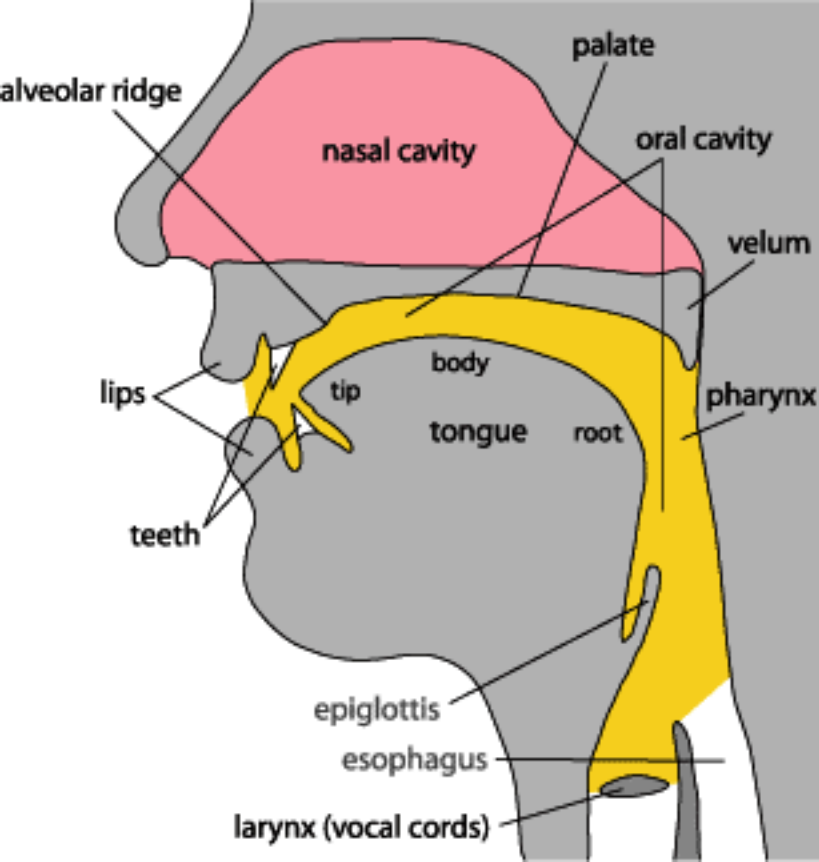
(b) Sagittal section of the left side of the head and neck showing the location of respiratory structures

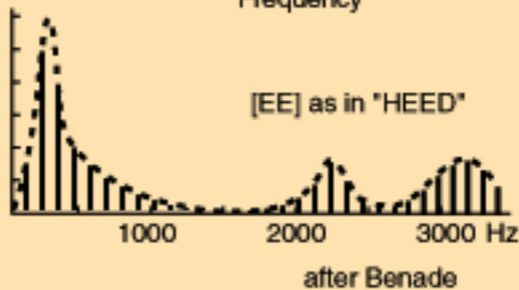
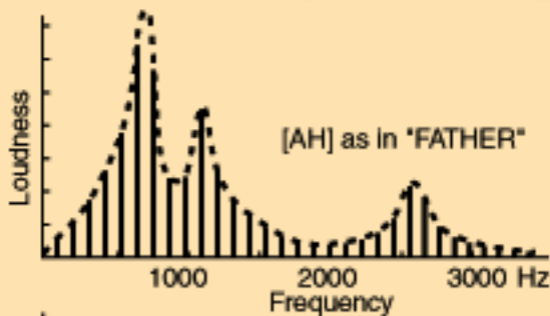
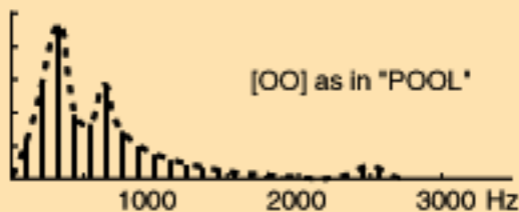


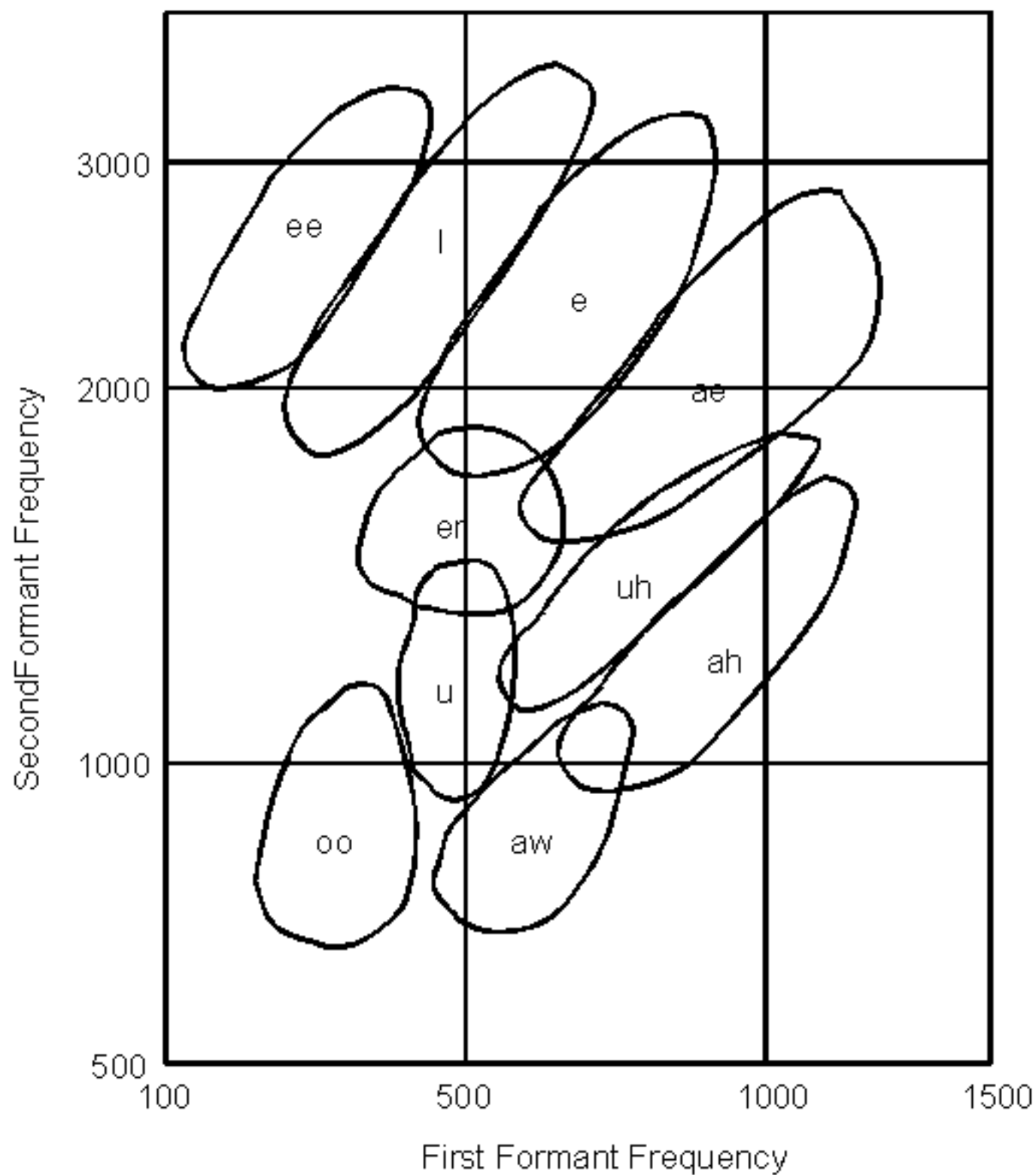
(c) Sagittal section











Second versus First Formant Frequency for Some Common Vowels